

CT Scan Technology

An Evolving Tool for Avoiding Complications and Achieving Predictable Implant Placement and Restoration

SCOTT D. GANZ, DMD / USA

Abstract

Implant dentistry, one of the most predictable treatment alternatives offered to patients who are missing teeth can be enhanced by thorough pre-surgical diagnosis and treatment planning efforts by all members of the implant team. Conventional radiologic techniques including periapical and panoramic radiographs are limited by the two dimensional interpretation of existing hard and soft tissue. The inherent distortion factor can misrepresent bone topography in critical areas associated with vital anatomy or potential implant sites. Advances in diagnostic radiological techniques improved with the introduction of CT scan technology for dental applications. The enhanced diagnostic range of this evolving technology empowers the clinician with ne-

cessary tools to avoid potential complications associated with implant dentistry.

The purpose of this paper was to identify valuable aspects of interactive CT through documentation and identification of several important issues; (1) revealing difficult to detect pathology, (2) correct assessment of bone trajectory to avoid iatrogenic damage, (3) use of CT scan / surgical templates to relate tooth-to-bone relationship, (4) choosing appropriate implant shape to fit residual bone, and (5) appreciation of sinus anatomy post augmentation procedures. It was concluded that interactive CT scan software applications provide state-of-the-art diagnostic tools which create the confidence to benefit both patient and clinician in the quest for achieving predictable results.

Introduction

Dental implants provide clinicians with an expanded set of treatment options to offer their patients. Implant dentistry can replace missing teeth in a known, acceptable, and highly predictable mode which has dramatically improved quality of life for millions of people. The conventional approach to treatment planning dental implants includes thorough clinical examination, panoramic radiography, diagnostic wax-up and mounted study models. Other diagnostic aids may include cephalometric films, periapical radiographs, and tissue or bone-mapping techniques for assessment of implant sites. Until recently the greatest emphasis was directed to the surgical aspect of implant placement, with less consideration for soft tissue, anatomical contour, emergence profile, occlusion, tooth morphology, or final prosthetic outcome.

Demand for dental implants has increased substantially during the past

20 years resulting in the need for improved methods to ensure the most favorable surgical position to restore the patient properly. Problems associated with implant failure or patient dissatisfaction are often related to poor diagnostic and treatment planning methods. Advanced diagnostic aids such as tomography, digital radiography, and CT Scan film allow for a more accurate presurgical evaluation. Perhaps the most important technological advancement which dramatically enhanced the clinician's ability to diagnose and treatment plan dental implants has been the CT scan. Although CT scans (Computerized Tomography) have been available for medical use since 1973 it was not until 1987 that this innovative technology became available for dental application. After referral to a radiologist, specially formatted diagnostic images were created from CT scan data to determine potential sites for placement of dental implants. The resultant radiographic films offered true, three dimensional visualization

of the bone for either maxillary or mandibular arches. The advent of CT Scan film technology allowed for an accurate assessment of bone height and width, identification of soft and hard tissue pathology, location of anatomical structures such as the inferior alveolar canal, and for measuring the vital qualitative dimensions necessary for proper implant placement.

Conventional periapical, panoramic, or tomographic images contain an inherent distortion factor which if unrecognized can lead to incorrect diagnosis. This distortion was virtually eliminated through advancements in CT Scan imaging techniques¹. In 1988 Columbia Scientific, Inc. (Columbia, Maryland, USA) developed 3D dental software that worked through standard GE CT Scanners. The addition of an intermediate computer workstation called an Imagemaster -101™ (introduced in 1990) allowed for further development and refinement of the diagnostic tools available to CT

scans for dental implants. Interfaces were then developed to process CT data from most CT Scanners available today.

The original limitations of CT Scan film were overcome in July of 1993 when SIM/Plant™ for Windows was

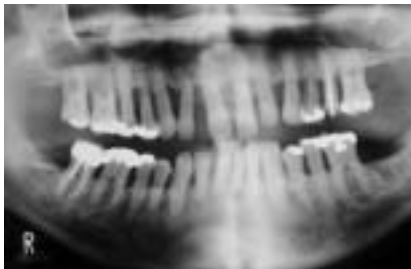


FIGURE 1 Conventional panoramic radiograph revealing advanced periodontal disease.

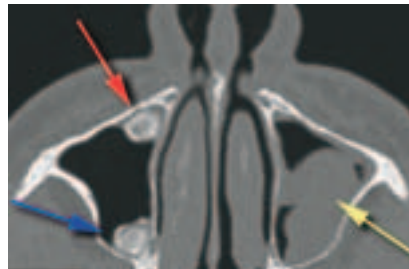


FIGURE 2 CT Axial 40 reveals anterior lesion (red arrow), posterior lesion (blue arrow), and pathology in left maxillary sinus (yellow arrow).

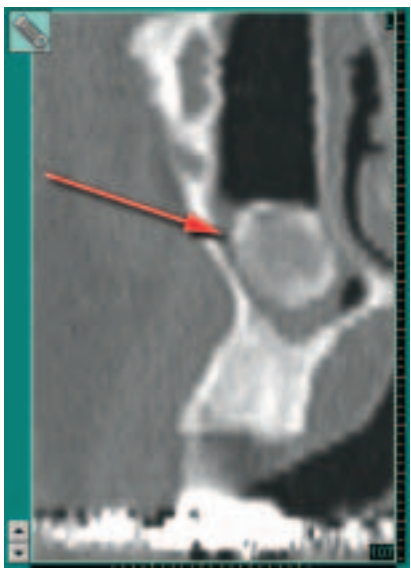


FIGURE 3 Cross-sectional slice 107 reveals a magnified view of the ovoid, calcified anterior lesion (red arrow).

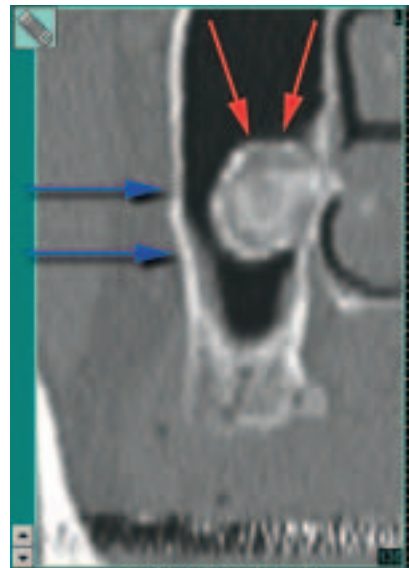

FIGURE 4 Cross-sectional slice 136 indicates the buccal plate (blue arrows) and the well-circumscribed posterior lesion (red arrow).

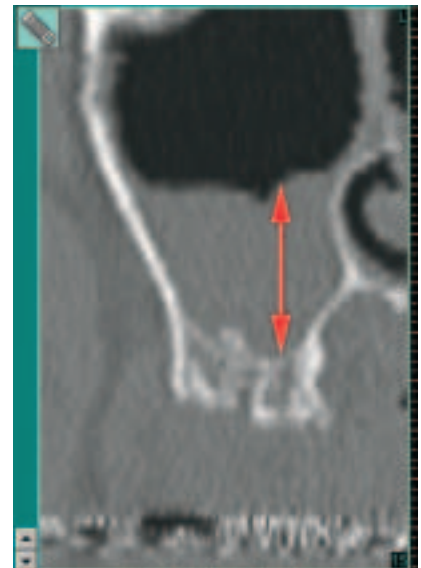

FIGURE 5 The extent of the soft tissue proliferation in the maxillary left sinus is measured at over 16mm as seen in cross-sectional slice 15.

released as an intuitive, user-friendly software interface for dentists to harness the power of CT technology for their patients. This interactive program fueled by improvements in the personal computer hardware and software provided by the Windows® platform revolutionized the world of diagnostic imaging. SIM/Plant™ for Windows® enabled the clinician to examine the CT Scan data in an environment which surpassed the limited information afforded by CT Scan film alone.

Once loaded into the doctor's computer SIM/Plant™ opened a whole new world of interactive diag-

nosis and treatment planning. This innovative software program allows the clinician to easily and quickly visualize all of the images which may exist in the film version of the CT Scan. Advanced 3-D reformatting techniques permit highly refined, accurate assessment of the CT Scan data in a manner which exceeds information gleaned from film alone. This state-of-the-art software offers the clinician an improved interactive diagnostic tool, superior to conventional CT Scan film. Significantly, film cannot relate information on bone density which is an important factor in determining an adequate location for osseointegration to occur. Since the development of SIM/Plant™ other similar applications have been introduced in the marketplace for the purposes of making CT scan technology available to clinicians around the world.

Enhancements offered by these software packages enable the clinician to dramatically improve diagnostic ability in a manner superior than the original radiographic film. Clinicians can quickly scan through all relevant graphical images without the need for a room full of light boxes. The interactive specifications of the software allow for "scrolling" through the distortion-free slices usually set at 1mm intervals for axial, cross-sectional, and panoramic views. Innovative digital tools have been developed to enhance the diagnostic quality of each image and improve the relationship between imaging and practical aspects of sur-

tion of sinus anatomy post augmentation procedures.

Clinical Documentation

The conventional panoramic radiograph remains as an excellent

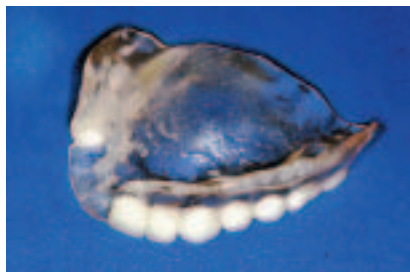

FIGURE 6 A clear acrylic template with full contour teeth which incorporate radiopaque barium sulfate for visualization on the CT scan.

tool to assess hard and soft tissues of the oral cavity. However, the two-dimensional panoramic radiograph delivers an inherently distorted image which can lead to incorrect diagnosis leading to incorrect treatment¹. A conventional panoramic radiograph presented in figure 1 reveals an advanced case of periodontal disease in both maxillary and mandibular arches. On closer inspection, a radiopaque area was noted superior to the apical roots of the maxillary right premolars. After a complete examination and diagnostic work-up the preliminary treatment plan called for extraction of all the maxillary teeth followed by placement of an immediate transitional complete denture. To regain the lost dentition it was planned to complete bilateral sinus augmentation procedures to create the necessary foundation for later fixture placement. To facilitate the diagnostic phase of the treatment plan work-up the patient was instructed to obtain a CT scan of the maxillary arch, and was referred to a radiology center for imaging.

The reformatted CT scan series revealed significant pathology undetected by the panoramic radiograph. The CT axial 40 view represented in figure 2 slices the maxilla superior to the floor of the nose. The outline of the nose can be seen at the top of the image with the inferior aspect of the

nasal concha clearly visible at the midline. The red arrow indicates what appears to be a calcified lesion located in the anterior aspect of the right maxillary sinus. The blue arrow points to a second lesion in the posterior aspect of the right maxillary si-

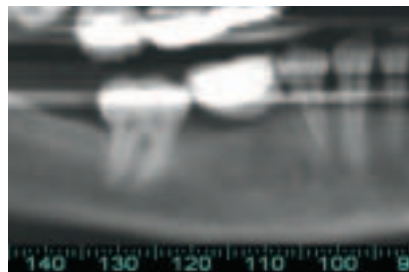


FIGURE 7 Reformatted panoramic view of missing mandibular first molar in radiopaque template.

nus. The yellow arrow shows an almost complete occlusion of the left maxillary sinus by a non-calcified or soft tissue-type lesion. The cross-sectional images reveal radiopaque, well-circumscribed, calcified lesions which are ovoid in shape and attached to the walls of the sinus by a soft tissue connection (figure 3, Slice 107 – anterior lesion and figure 4, Slice 136 – posterior lesion). The near occlusion of the left maxillary sinus represents soft tissue polyps which were measured at over 16 mm in height from the sinus floor (figure 5). As this patient was scheduled for a bilateral sinus augmentation post-extractions, the radiographic findings obtained through the CT scan were significant to alter the plan of treatment.

Certainly the advanced images afforded by the three dimensional CT scan offer the clinician further insight into the anatomical structures necessary for proper diagnosis, treatment planning and execution of proposed treatment. To further enhance the practical application of this evolving technology, CT scan templates can be fabricated to help guide the placement of endosteal implants. Tooth position should be the ultimate guide in determining implant placement, as implant dentistry is a restoratively driven entity^{2,3}. To that end, templates are fabricated from a complete

diagnostic work-up which includes mounted study casts, and a formulation of the restorative plan. From this plan, an acrylic template is fabricated to incorporate a radiopaque substance (usually barium sulfate) which can be easily identified on the CT scan image, and sometimes the addition of tubes of titanium for directional guidance^{4,5,6}. A full contour wax-up or the patient's existing denture if appropriate can be duplicated in clear acrylic, with missing teeth replaced by the barium sulfate/acrylic mixture (figure 6). The patient should be instructed to wear this template during the process of CT scan imaging. The radiopaque teeth will then appear in the CT image as indicators to potential implant sites.

Upon evaluation of the CT scan image incorporating a properly fabricated radiopaque template, the underlying bony anatomy can be visualized in direct relationship to the desired tooth position. In the following example, a single mandibular first molar was missing leaving a mesial-distal space of approximately 14 millimeters (figure 7). Cross-sectional slices, one millimeter apart reveal the full buccal-lingual dimension, inclination, trajectory of the bone within the framework of the missing tooth to be replaced (figure 8). For such a wide space it was anticipated that two implants would be better utilized than a single implant to avoid any potential cantilever forces. Cross-sectional slices 110 – 112 indicate the relationship in the area where the first anterior implant could be placed. The blue arrow representing the straight line anatomy of the lingual cortical plate. Implant placement parallel to the lingual cortical plate, surrounded by adequate bone could be achieved guided by the template position. However, within a few millimeters posterior (slices 116 – 118) the straight line changed representing the lingual concavity which is usually present in the posterior molar region of the mandible (figure 9). This concavity, if overlooked can result in perforation of the lingual cortical plate during the

preparation of the osteotomy or when the implant is placed⁷. Additionally, if too wide an implant is chosen it can inadvertently create a perforation which could result in fistula formation or the eventual loss of the fixture (figure 10A). This type of perforation can occur in the maxillary arch as well.

Pre-surgical understanding of existing anatomy such as a lingual or

adequate width of supporting bone with sufficient vascular supply (figure 10B). The desired emergence profile can be visualized in the planning stages with the restorative tools found in the latest version of SIM/Plant™ (Version 6.03) which is helpful in fabrication and orientation of the guide holes for the actual template to be used during the surgical procedure.

casual mistakes occur which might be avoided with proper diagnostics and surgical technique. As previously mentioned, perforations can occur when the existing bone anatomy is not fully appreciated. This unfortunate error is magnified when considering the great effort to regenerate new bone from grafting procedures to facilitate implant placement. The cross-sectional slice as

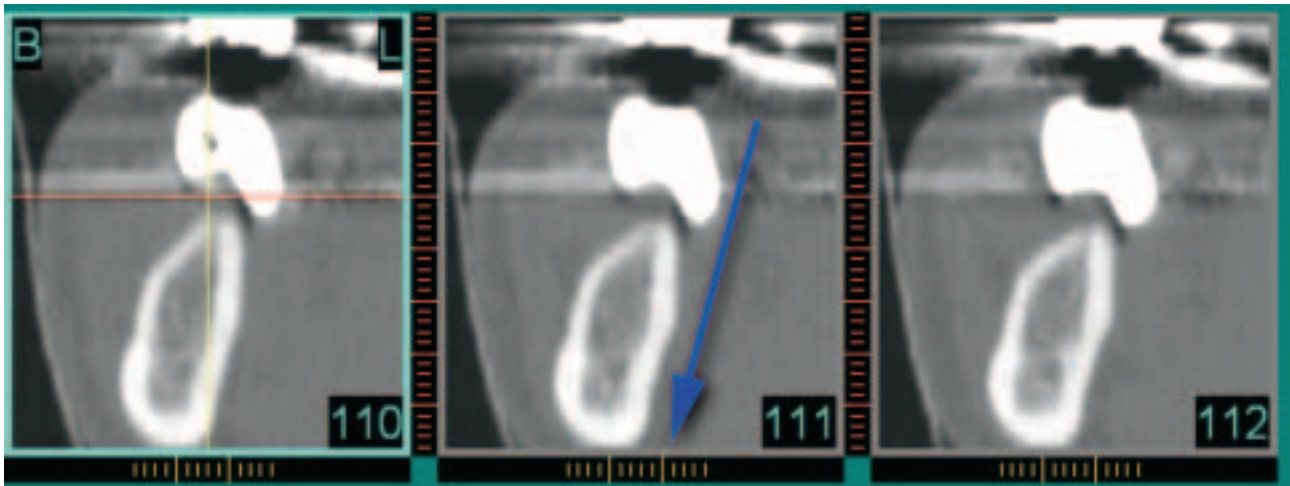

FIGURE 8 Cross-sectional slices 110–112 clearly show the molar tooth in relation to the underlying bone. Blue arrow indicates the straight lingual cortical plate.

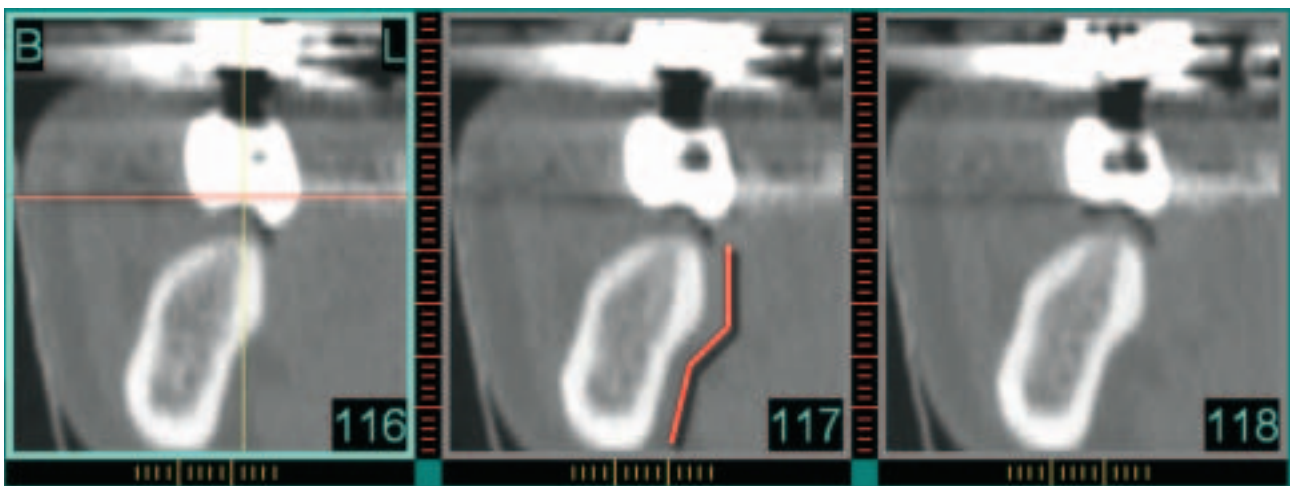


FIGURE 9 Cross-sectional slices 116–118 reveal the change in contour of the lingual plate as indicated by the red arrow.

buccal concavity may lead the clinician to choose an implant shape which would maximize the existing anatomical variation of the bone without sacrificing a wide occlusal table necessary to support a molar restoration. A tapered implant design could be used to help avoid such a bony concavity and ensure that the implant is surrounded by an

The sinus augmentation procedure has become a very predictable treatment alternative to gain additional sites for subsequent implant placement and prosthetic reconstruction. However few clinicians avail themselves of the imaging tools which can give a true 3-D picture of the sinus cavity. While most sinus procedures are successful, oc-

illustrated in figure 11A reveals a perforation of the buccal plate by an implant fixture in a post sinus augmentation CT scan. The radiopaque surgical template seen hovering above the alveolar bone, is evidence that the bulk of newly generated bone was by-passed during the surgical placement of the implant. In figure 11 B, a red “triangle”

delineates the cross-sectional area of the greatest amount of bone volume which was created in the sinus. This "triangle of bone" can be bisected (yellow arrow) to maximize the positioning of the implant fixture in the greatest volume of bone as described by GANZ⁸. For this example, a custom angulated or angled abutment would be utilized to re-direct the transmucosal ele-

During surgery on the mandibular arch the patient's jaw position can be critical especially when an accurate template is not utilized. What appeared to be a correctly aligned implant may in actuality be mal-positioned. When the surgeon is incorrectly orientated, it is even possible to perforate the anterior symphysis of the mandible. Figure 12 illustrates a reformatted pano-

be appreciated in the axial view seen in figure 14. The red arrows indicate the thin residual lingual cortical plate, and the blue arrow pointing to the implant place in the left mandible. The failures can be directly related to the perforation of the lingual cortical plate as indicated by figure 15A. The simulated implant found in figure 12, is positioned to indicate the apparent po-

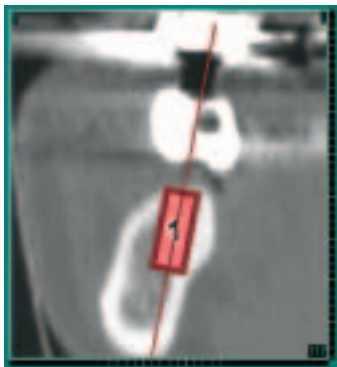


FIGURE 10A Wide body implants could inadvertently lead to perforation of the lingual plate.

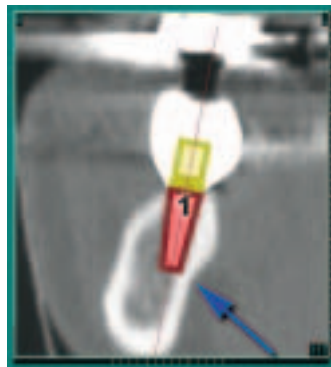


FIGURE 10B A wide emergence platform can be maintained with a tapered design implant.

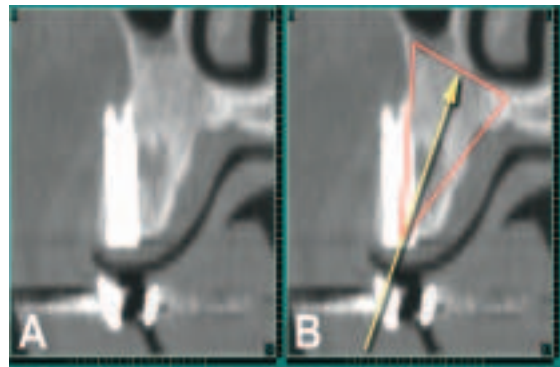


FIGURE 11A Buccal perforation of an implant which missed the sinus augmented bone.

FIGURE 11B The "triangle of bone" concept illustrates the greatest bone volume seen in cross-section.




FIGURE 12 Reformatted panoramic image revealing two remaining implants and one simulated implant.

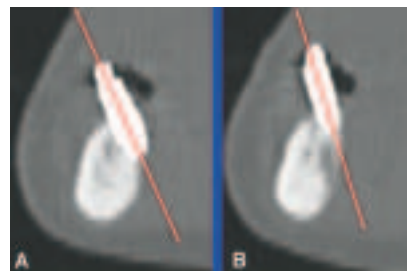


FIGURE 13 A and B The severe buccal angulation of the right and left remaining implants.

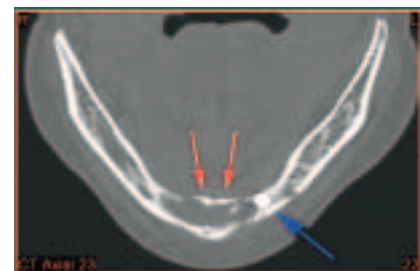


FIGURE 14 Axial view shows the extent of bone loss between the buccal and lingual cortical plates (red arrows). Blue arrow points to remaining left implant.

ment into the correct position and required emergence profile to produce the final functional and esthetic restoration. Prior planning and visualization of the relationship between the underlying bone and the desired tooth position is essential to surgical/ restorative success and avoidance of potential complications of fixture perforation. The ability to evaluate the three-dimensional aspect of sinus cavity topography, or other bone defects has enabled clinicians to plan and predict innovative grafting procedures creating additional treatment solutions and restorative alternatives for our patients^{9,10,11}.

ramic image with two remaining implants out of the four originally placed. The simulated implant has been added for orientation purposes. Even the reformatted panoramic image presents difficulty in analyzing the residual bone in the symphysis, or the apparent angulation of the implants because this is still only a two dimensional view. The severe buccal inclination of the two remaining implants can be clearly ascertained in cross-sectional images seen in figures 13A and 13B. This CT scan was taken after four of the six implants had failed. The amount of bone destruction (post implant failure) can

sitioning of the failed implant figure 15B. This patient was successfully rehabilitated after regenerative bone grafting procedures and subsequent placement of four implants parallel to the true trajectory of the remaining bone.

CT scan technology is an evolving entity as evidenced by advances made possible with the increasing speed of personal computing power. Faster, improved-performance Pentium-class computer processors have allowed for the development of CAD CAM, three dimensional representations of bone to be manipulated on screen, and when required to produced as ra-

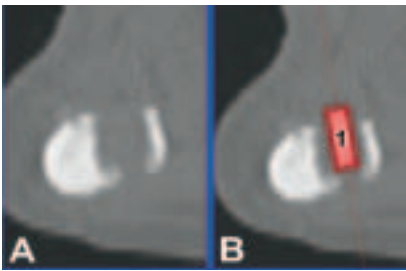


FIGURE 15A The cross-sectional view relates the extent of the perforation caused by the failed implant.

FIGURE 15B The simulated implant indicates the previous position of the failed implant.

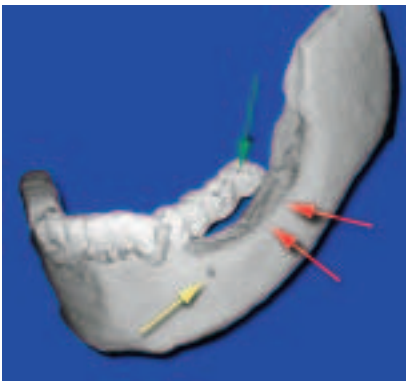


FIGURE 16 A three-dimensional mandibular model with green arrow indicating radiopaque template, red arrows indicating loss of posterior alveolar bone, and yellow area revealing the mental foramen.

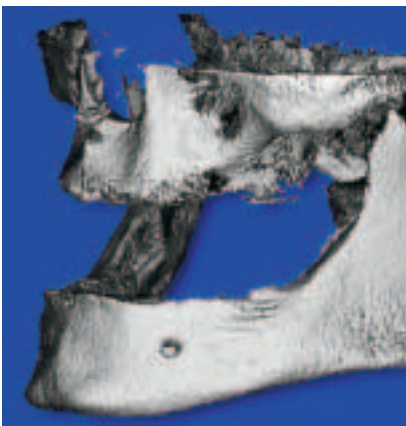


FIGURE 17 New technology allows for both maxillary and mandibular arches to be imaged together.

pid prototype models. These 3-D on-screen models take the visualization of anatomy to a new level of understanding and appreciation. When coupled with properly designed templates, diagnosis, treatment planning, and execution of the proposed plans can be realized on the computer prior to anyone touching the patient. Figure 16 illustrates a three dimensional representation of a mandible with a

CT scan template of proposed tooth restoration. The radiopaque teeth (green arrow) can be seen over the volumetric loss of bone evident by the red arrows. The mental foramen is indicated by the yellow arrow. Newly developed CT scan like machines can now image both maxillary and mandibular arches during one session. These exciting new images will allow clinicians to envision the relationship of the entire maxillo-mandibular complex (figure 17). As technology advances, clinicians will be able to evaluate interarch space, vertical dimension, occlusion, TMJ, and pathology with improved methods for more accurate assessments for pre-surgical and pre-prosthetic planning.

Conclusion

Implant dentistry is one of the most predictable treatment alternatives that can be offered to patients who are missing teeth. Predictability is enhanced by thorough pre-surgical diagnosis and treatment planning efforts by all members of the implant team. However, radiologic techniques including periapical and panoramic radiographs are limited in the ability to provide clinicians with only a two dimensional interpretation of existing hard and soft tissue. The inherent distortion factor can misrepresent bone topography in critical areas associated with vital anatomy or potential implant sites. Advances in diagnostic radiological techniques dramatically improved with the introduction of CT scan technology for dental applications. Limitations in CT scan film have been overcome with interactive software applications which are available for the desktop or laptop computer under the Windows® operating system.

Clinical examples were utilized to demonstrate the three-dimensional capability of interactive CT as it applied to practical clinical situations. The enhanced diagnostic range of

this evolving technology empowers the clinician with necessary tools to avoid potential complications associated with implant dentistry. This technology has been found to be helpful in other areas such as pre-surgical planning for bone grafting procedures. Interactive CT scan software applications provide state-of-the-art diagnostic tools which create the confidence to benefit both patient and clinician in the quest for achieving predictable results.

Author's address:

Scott D. Ganz, DMD

158 Linwood Plaza – Suite 204

Fort Lee, N.J. USA 07024

Phone: +1-201-592-8888

Fax: +1-201-592-8821

E-mail: sdgimplant@drganz.com

Internet: www.drganz.com

References

- 1 Sonick, Michael, "A Comparison of the Accuracy of Periapical, Panoramic, and Computed Tomographic Radiographs in Locating the Mandibular Canal." *JOMI*, 1994;9:455-460.
- 2 Ganz, S.D. What is the Most Important Aspect of Implant Dentistry? *The Implant Society, inc.*, Vol. 5 No. 1, 1994.
- 3 Garber, D.A. Restorative-Driven Implant Placement with Restoration-Generated Site Development. *Compendium*, Vol. 16; No. 8, 1995: pp 796-804.
- 4 Klein, M, Cranin AN, and Sirakian A. A computerized tomograph (CT) scan appliance of optimal presurgical and preprosthetic planning of the implant patient. *Pract Perio and Aesth Dent* 5(6); 1993:33-39.
- 5 Amet, E.M., and Ganz, S.D. Functional and Aesthetic Acceptance Prior to Computerized Technology for Implant Placement. *Implant Dentistry*. Vol (6);6, 1997: pp 193-197.
- 6 N. U. Zitzman, and Marinello, C.P. Treatment Plan for Restoring the Edentulous Maxilla with Implant-Supported Restoration: Removable Overdenture versus Fixed Partial Design. *J Prosthet Dent*. 1999;82: 188-196.
- 7 Ganz, S.D. "Utilizing CT Scan Technology to Survey Anatomical Sites for Wide Body Implant Placement" Paper Presented at the 45th Meeting of the American Academy of Implant Dentistry. Caesar's Palace. Las Vegas, Nevada. Nov 12, 1996. On-Going Research Project.
- 8 Ganz, S.D. "The Triangle of Bone - A Formula for Successful Implant Placement and Restoration" *The Implant Society, Inc.* Vol (5);5, 1995:pp2-6.
- 9 Ganz, S.D. Mandibular Tori as a source for on-lay bone graft augmentation. *A Surgical Procedure*. *Pract Perio and Aesth Dent*. *The Implant Report*. Vol (9);9, 1997 pp 973-982.
- 10 Rothman, Stephen L.G. Computerized Tomography of the Enhanced Alveolar Ridge. In: *Dental Applications of Computerized Tomography*, Chicago. Quintessence Publishing Co., Inc. 1998:pp 87-112.
- 11 Krekmanov L., Placement of Posterior Mandibular and Maxillary Implants in Patients with Severe Bone Deficiency: A Clinical Report of Procedure. *Int J Oral Maxillofac Implants* Vol (15);5, 2000: pp 722-730.